

# Detecting Caries at the Restoration Margins: Clinical Challenge, Technological Solution — The Canary System

*Stephen Abrams, DDS*

There are many reasons for the replacement of restorations including esthetics, loss of anatomical form, fracture and loss. Secondary caries is, however, the major factor.<sup>1-3</sup> The detection of secondary caries in its early stages is not easy,<sup>4</sup> especially with current detection methods including radiography, explorer and visual examination.

Discoloration next to the restoration or ditched amalgam margins are not necessarily predictive of secondary caries.<sup>5</sup> Bitewing ra-

diographs may not be the ideal detection tool in detecting enamel secondary caries,<sup>6-8</sup> particularly if they are located on the occlusal or smooth surfaces. The restoration also masks the ability of radiographs to detect caries along the preparation walls.<sup>9</sup> All of these factors create clinical challenges for the practitioner.

There are various caries detection devices on the market today but they have their limitations, especially fluorescence-based devices. A number of studies have

concluded that measuring fluorescence is not suitable for detecting caries around restoration margins or beneath dental sealants due to false positive readings.<sup>10-13</sup> The CR Clinicians' Report (March 2012) found that existing restorations interfered with readings.<sup>14</sup> Further, fluorescence does not give any information about lesion size or depth, and does not penetrate beneath the tooth surface due to the scattering of light from stain, plaque, organic deposits and surface features such as pits and fissures.<sup>15,16</sup>

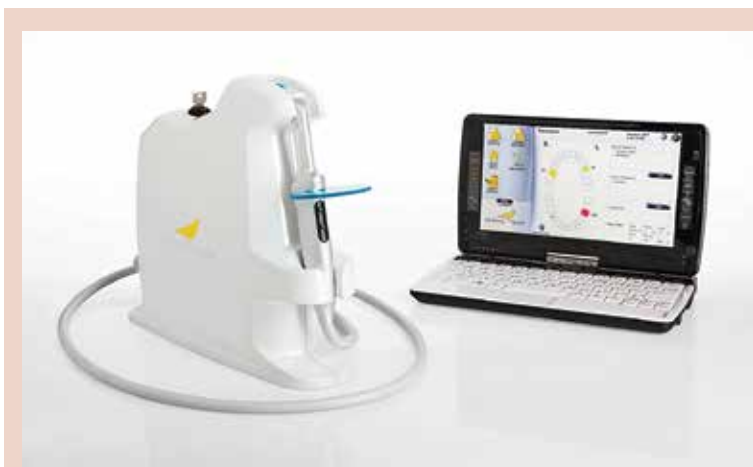

FIGURE 1—The Canary System.

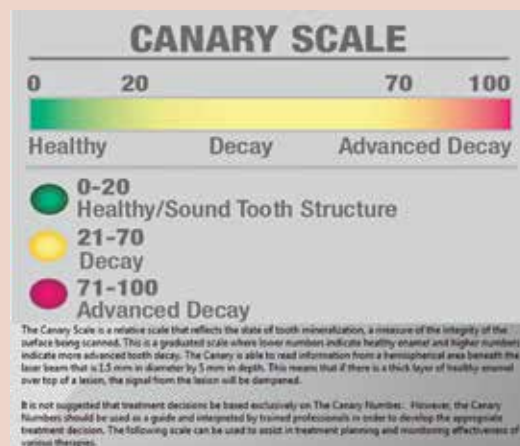
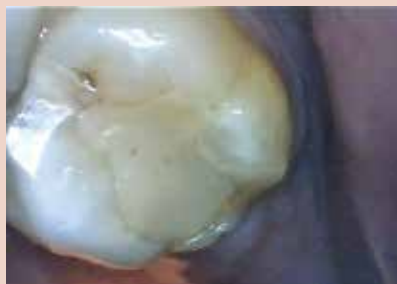

FIGURE 2—The Canary Scale.

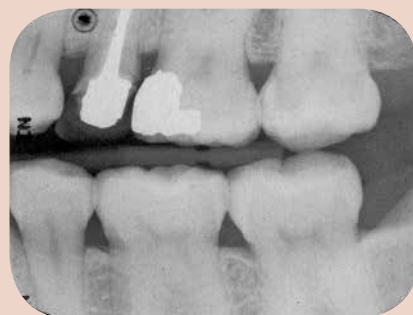The Canary System, (Fig. 1) uses energy conversion technology (PTR-LUM) to image and examine the tooth. Pulses of laser light are aimed at the tooth, and the light is then converted to heat (Photothermal Radiometry or PTR) and light (luminescence or LUM), which are emitted from the tooth surface between pulses. These harmless pulses of laser light enable the clinician to examine sub-surface caries up to 5mm below the surface.<sup>17,18</sup>

Caries modify the thermal properties (PTR) and glow (LUM) of healthy teeth. As a lesion grows, there is a corresponding change in the signal. In effect, the heat confined to the region with crystalline disintegration (dental caries) increases the PTR and decreases the LUM. As remineralization progresses and enamel prisms start to reform their structure, the thermal and luminescence properties begin to revert towards those of healthy tooth structure.<sup>19-21</sup>

The Canary System creates a Canary Number (ranging from 0–100) from an algorithm combining the PTR and LUM readings, which are directly linked to the status of the enamel or root surface crystal structure<sup>22</sup> (Fig. 2). A Canary Number of less than 20 indicates healthy crystal structure. A Canary Number greater than 70 indicates a large lesion that may justify restoration. Canary Numbers falling between 20 and 70 indicate the presence of early carious lesions or cracks that may require restoration, particularly at restorative margins.<sup>23</sup> If the caries is located beneath a healthy layer of enamel, the Canary measures both healthy tissue and caries. The healthy crystal structure overlying the caries dampens the signal, decreasing The Canary Number.



**FIGURE 3**—Occlusal view of the maxillary second molar.



**FIGURE 4**—Bitewing radiographs left side.

Research has shown that The Canary System can detect caries around the margins of restorations.<sup>24-27</sup> The following case report provides an excellent example of how The Canary System can be used to detect caries around the margins of restorations.

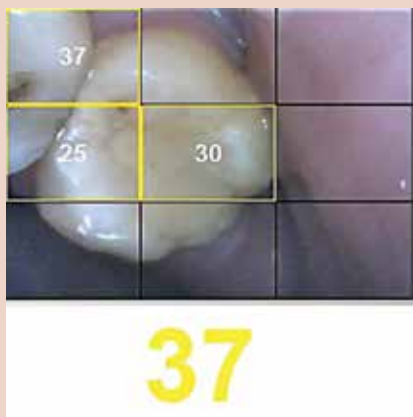
#### CASE REPORT

A 30-year-old male was seen at his re-care appointment complaining of pain in the left posterior teeth. Visual examination (Fig. 3) and bitewing radiography (Fig. 4) did not reveal any pathology. There was a brown stain associated with the mesial marginal ridge of the maxillary left second molar but otherwise, the restoration seemed intact.

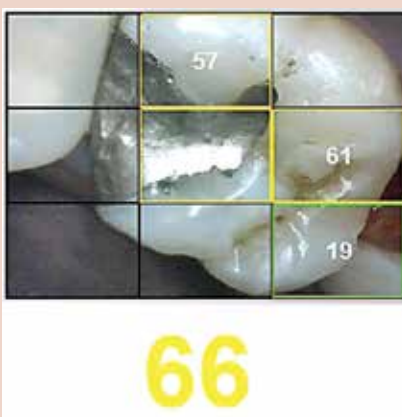
The Maxillary Left First and Second Molars were scanned with The Canary System. The Canary scan of the second molar (Fig. 5) indicated caries in the brown pit at the mesial marginal ridge, caries along the buccal margin of the composite, and possibly caries along the lingual aspect of the mesial marginal ridge. The Canary Scan of the first molar (Fig. 6) indicated caries on the distal proximal contact as well as caries around the buccal margin of the amalgam. Since The Canary Scan taken at that time indicated that both restorations needed to be opened and investigated, no further scanning was needed.

On opening the mesial marginal ridge of the second molar, extensive caries was detected (Fig. 7) in the mesial contact area. Caries and leakage were also found on the buccal margin at the distal aspect of the tooth. Since the caries on the mesial aspect was located beneath a 4 mm thick ridge of enamel, The Canary Number was dampened but still indicated that a lesion was present.

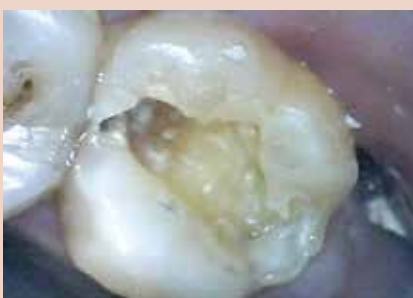On opening and removing the restorations on the maxillary first molar (Fig. 8), extensive caries were found along the walls of the amalgam and also in the interproximal region. In this situation, the caries was extensive in both the mesial and distal areas. In the distal interproximal region, the caries was large, close to the occlusal surface and located towards the buccal aspect of the contact area resulting in a Canary Number of 61. On the mesial aspect around the margin of the amalgam, the caries was large with Canary Numbers of 57 and 66 on the buccal and lingual walls of the restoration. This is a good example of how The Canary System can scan and detect caries beneath intact enamel surfaces, around restorations and in interproximal contact regions. Even with intact enamel overlying the lesion, The Canary was able to detect caries which were not seen on the bitewing radiograph.



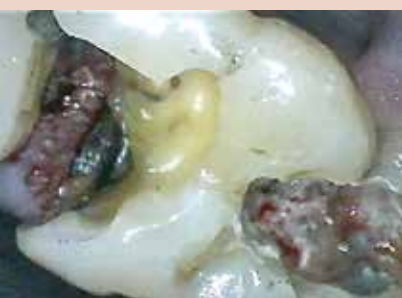**FIGURE 5**—Canary scan of the maxillary second molar.



**FIGURE 6**—Canary scan of the maxillary first molar.



**FIGURE 7**—Large caries found on the mesial aspect of the second molar and caries along the buccal margin.



**FIGURE 8**—Large caries found on the mesial and distal aspects of the first molar.

## SUMMARY

Caries is a disease that results in the destruction of the crystal structure of the tooth. The ability to examine crystal structure integrity has a direct impact on the effectiveness of the treatment plan. Detecting caries around the margins of restorations and in interproximal regions is a challenging situation. Visual examination and radiography all have limitations in terms of their ability to detect, diagnose and monitor caries. While visual examination addresses the tooth surface, early lesions typically begin and grow beneath. Using an explorer to probe lesions is often inaccurate, and can damage tooth structure and inoculate the pits and fissures with oral bacteria. Dental radiographs can detect interproximal lesions, but only after they've demineralized at least 60% of the outer enamel shell. Even at this stage, they do not provide an

accurate system to measure and monitor lesion size.

Fluorescence-based devices are designed to detect surface changes such as stain and bacterial by-products, but they are not capable of identifying early-stage pathological changes or cracks in crystal structure. The Canary System, uniquely powered by the energy conversion technology (PTR-LUM) has the ability to quantifiably identify defects in the structure of teeth. With this technology, dental clinicians for the first time have the ability to identify and measure crystal structure defects more accurately, and detect caries in clinically challenging situations.

## Disclosure:

Dr. Stephen Abrams is the President and Co-Founder of Quantum Dental Technologies which has developed The Canary System

mentioned in this article. He has not received any compensation for the preparation of this article. **OH**

*Stephen Abrams is a general dental practitioner with over 33 years of clinical experience. Upon graduation from the University of Toronto, Faculty of Dentistry in 1980, he established a group practice in Toronto Canada which has grown to involve both general dentists and dental specialists. He is a fellow of the Pierre Fauchard Academy, the Academy of Dentistry International and the American College of Dentistry. He is a member of the European Association for Caries Research and International Association of Dental Research. He has published over 90 articles in various international publications on topics ranging from early caries detection, and prevention to removable prosthetics and restorative dentistry. In 2002, Dr. Abrams was awarded the Barnabus Day Award from the Ontario Dental Association for 20 years of distinguished service to the dental profession. He can be contacted at (416)-265-1400 or email [dr.abrams4cell@sympatico.ca](mailto:dr.abrams4cell@sympatico.ca)*

**Disclaimer:** Dr. Abrams founded Quantum Dental Technologies, a company developing laser-based technology for the early detection and ongoing monitoring of dental caries.

*Oral Health welcomes this original article.*

## REFERENCES

- Kidd EA. "Diagnosis of secondary caries." *J Dent Educ*. 2001;65(10):997-1000.
- Mjör, I. A., Jacquelyn E. Moorhead J. E., Jon E. Dahl J. E., "Reasons for replacement of restorations in permanent teeth in general dental practice" *International Dental Journal* HYPERLINK "<http://onlinelibrary.wiley.com.myaccess.library.utoronto.ca/doi/10.1111/ijdj.2000.50.issue-6/issuetoc>" Volume 50, Issue 6, pages 361-366, December 2000
- Palotie U, Vehkalahti MM "Reasons for replacement of restorations: dentists' perceptions." *Acta Odontol Scand* 2012; 70: 485-490
- Kidd EA, Toffenetti F, Mjor IA. "Secondary caries.", *Int*



## Winter Clinic 2014 IS ON THE MOVE!

**The Toronto Sheraton Centre  
November 14, 2014**

**Winter Clinic 2014 is the  
opportune time for the entire  
dental team to Network with  
your colleagues in an engaging  
environment designed perfectly  
for you**

Announcing the First of Many  
**Core 1 Programs** by  
Peter L. Jacobsen, PhD, DDS

Fighting Dental Disease; Drugs,  
Bugs and Products  
What to Prescribe!

Dentist and hygienists know about  
prophylactic antibiotics for heart  
problems.

However, what about products  
for prosthetic joints and  
augmentation implants?

Your patients trust you to  
make the right decisions and  
recommendations on their behalf.

In this session the noted Dr.  
Jacobsen will explore the benefits  
and disadvantages of prescribed  
dental drugs and over-the counter  
products.

He will bring you up to date  
on a wide range of prescription  
drugs and over-the-counter  
dental products; discuss the  
various "active ingredients"  
while, providing you with a  
better understanding of oral care  
products. Dr. Jacobsen's wit and  
charm will entertain you while  
focusing on clinical realities that  
are important for your dental  
practice.

See you at the  
**Sheraton Centre!**



For more information visit  
**www.tordent.com**

UNCONVENTIONAL



Dent J. 1992;42(3):127-38.

5. Kidd EA, Joyston-Bechal S, Beighton D. "Marginal ditching and staining as a predictor of secondary caries around amalgam restorations: a clinical and microbiological study." J Dent Res. 1995;74(5):1206-11.
6. Bamzahim M, Shi XQ, Angmar-Mansson B. "Secondary caries detection by DIAGNOdent and radiography: a comparative in vitro study". Acta Odontol Scand. 2004;62(1):61-4.
7. Ekstrand KR, Ricketts DNJ, Kidd EAM. Reproducibility and accuracy of three methods for assessment of demineralization depth of the occlusal surface: an in vitro examination. Caries Res. 1997;31(3):224-31.
8. Rocha RO, Ardenghi TM, Oliveira LB, Rodrigues CRMD, Ciamponi AL. In vivo Effectiveness of Laser Fluorescence Compared to Visual Inspection and Radiography for the Detection of Occlusal Caries in Primary Teeth. Caries Res. 2003;37(6):437-41.
9. Espelid I, Tveit AB, Erickson RL, Keck SC, Glasspoole EA. Radiopacity of restorations and detection of secondary caries. Dent Mater. 1991;7(2):114-7.
10. Gostanian HV, Shey Z, Kasinathan C, Caceda J, Janal MN. "An in vitro evaluation of the effect of sealant characteristics on laser fluorescence for caries detection." Pediatr Dent 2006;28(5):445-50
11. Hosoya Y, Matsuzaka K, Inoue T, Marshall GW Jr. "Influence of tooth-polishing pastes and sealants on DIAGNOdent values." Quintessence Int 2004;35(8):605-11.
12. Lussi A, Reich E. "The influence of toothpastes and prophylaxis pastes on fluorescence measurements for caries detection in vitro." Eur J Oral Sci 2005;113(2):141-4.
13. Hitij T, Fidler A. "Effect of dental material fluorescence on DIAGNOdent readings." Acta Odontol Scand 2008;66(1):13-7.
14. Christensen G J. "New Caries Detection Systems: Reliable and Accurate." Clinicians Report Mar 2012;5(2)..
15. Liang R, Wong V, Marcus M, Burns P, McLaughlin P. "Multimodal imaging system for dental caries detection." Proc. SPIE 6425, Lasers in Dentistry XIII, 642502 February 2007
16. Hall A, Girkin JM. "A review of potential new diagnostic modalities for caries lesions." J Dent Res 2004;83 Spec No C:C89-94.
17. Jeon, R.J., Phan TDT, Wu, A., Kulkarni, G., Abrams, S.H., and Mandelis, A., "Photothermal radiometric quantitative detection of the different degrees of demineralization of dental enamel by acid etching", Proc. 13th Int. Conf. Photoacoustic & Photothermal Phenomena, July 5 – 8, 2004, J. Physique IV France, 2005: 125: 721 - 723
18. Jeon R.J., Matvienko A., Mandelis A., Abrams S.H., Amaechi B.T, Kulkarni G. "Detection of interproximal demineralized lesions on human teeth in vitro using frequency-domain infrared photothermal radiometry and modulated luminescence", J. BioMed. Optics, 2007; 12(3): 034028 1 – 13
19. Matvienko, A., Jeon, R. J., Mandelis, A., Abrams, S. H., Amaechi, B. T., "Photothermal Detection of Incipient Dental Caries: Experiment and Modeling", Proc. of SPIE, 2007, 66759; 67590J-1 - 67590J-10
20. Jeon R. J., Hellen A., Matvienko A., Mandelis A., Abrams S. H., Amaechi B. T., Experimental Investigation of Demineralization and Remineralization of Human Teeth Using Infrared Photothermal Radiometry and Modulated Luminescence, (SPIE BIOS, San Jose, USA, January 2008), Proc. SPIE Vol. 6856, 68560B (2008); DOI:10.1117/12.763807
21. Matvienko A., Mandelis A., Abrams S.H., Robust multi-parameter evaluation method of optical and thermal properties of a layered tissue structure using photothermal radiometry. Applied Optics, 2009; 48(17): 3193-3204
22. Garcia, J., Mandelis, A., Abrams, S. H., Matvienko A., "Photothermal Radiometry and Modulated Luminescence: Application to Dental Caries Detection", Chapter 71 page 1047, published in "Handbook of Biophotonics, Vol. 2: Photonics for Health Care" editors: Jürgen Popp (Editor), Valery V. Tuchin (Editor), Arthur Chiou (Editor), Stefan H. Heinemann (Editor) December 2011, Wiley-VCH
23. Abrams, S. H., Sivagurunathan, K., Jeon, R. J., Mandelis, A., Silvertown, J. D., Hellen, A., Hellen, W. M. P., Elman, G. I., Ehrlich, B. R., Chouljian, R., Finer Y., and Amaechi, B. T., "Multi-Center Clinical Study to Evaluate the Safety and Effectiveness of 'The Canary System' (PTR-LUM Technology)". Caries Res. 2011; 45:174-242 [58th Annual ORCA Congress July 6-9, 2011, Kaunas, Lithuania].
24. Kim, J., Mandelis, A., Matvienko, A., Abrams, S. H., Amaechi, B. T., "Detection of Dental Secondary Caries Using Frequency – Domain Infrared Photothermal Radiometry (PTR) and Modulated Luminescence (LUM)", International Journal of Thermophysics 2012 (December) 33: 1778 – 1786
25. Abrams, S. H., "Detecting Caries at the Margins of Restorations with The Canary System", Dental Tribune 2012 (May); 6: 14
26. Kim, J., Mandelis, A. Matvienko, A. Abrams, S. H., Amaechi B. T., "Detection of Dental Secondary Caries Using Frequency-Domain Infrared Photothermal Radiometry (PTR) and Modulated Luminescence" (LUM) XVI International Conference on Photoacoustic and Photothermal Phenomena, November 2011
27. Wong, B., Abrams, S. H., Silvertown, J. D., Sivagurunathan, K., Klausze, R., Mandelis, A., Amaechi, B. T. "Detection of caries around ceramic crown restorations with The Canary System and DIAGNOdent". ORCA Abstract # 86, Caries Res 2013;47:433-531 [60th ORCA Congress. July 3-6, 2013, Liverpool, UK].